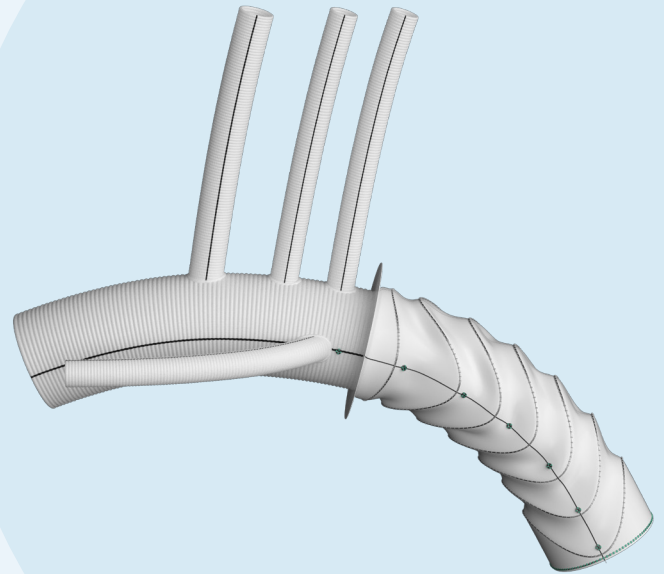
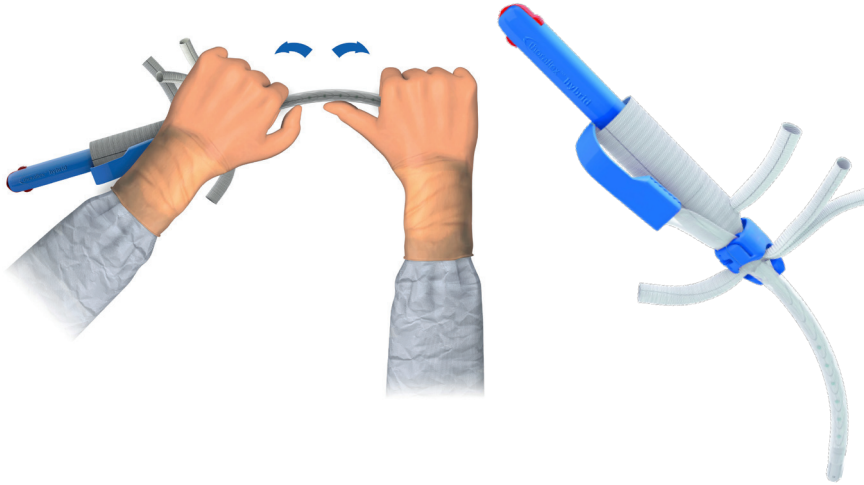


thoraflex™ hybrid

Conforming Arch
Surgery to the
Gold Standard



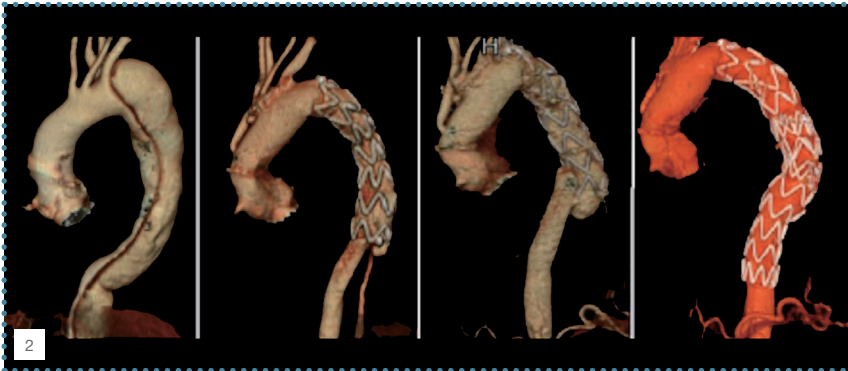
Flexible by Design, Navigating the Curve



“Thanks to the **malleable shaft**, the stented part can be shaped to conform to the isthmus and descending aorta anatomy. This makes the device **less traumatic on the descending aortic wall and easier to introduce into the aorta.**”¹


Flexible Ring Stent Design

- ▶ Reduces radial force on the aortic wall³
- ▶ Minimizes risk of intimal injury³



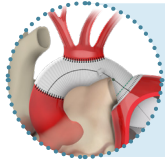
Z-Stent FET - Angio-CT 3D reconstruction of type B aortic dissection before surgery (A), after FET procedure (B), dSINE detection (C) and result after TEVAR (D).

CT, computed tomography; 3D, three-dimensional; FET, frozen elephant trunk; dSINE, distal stent graft-induced new entry; TEVAR, thoracic endovascular aortic repair.²

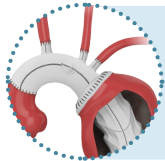
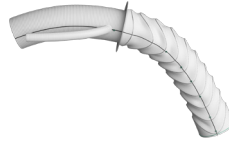


1. Ruggieri et al. “Multibranch hybrid device for frozen elephant trunk: what does it change?” The Journal of Thoracic & Cardiovascular Surgery, 2015; 15(1), 253-255.
 2. Murana et al. “Distal stent graft-induced new entry (dSINE) after frozen elephant trunk: a scoping review.” Cardiovascular Diagnosis & Therapy, 2023; 13(2), 408-417.
 3. Ma et al. “Open stented grafts for frozen elephant trunk technique: Technical aspects and current outcomes.” Aorta, 2015; 3(4), 122-135.


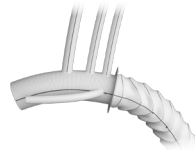
Versatility in Treatment, Solutions for Each Patient



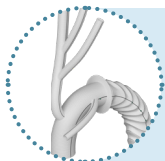
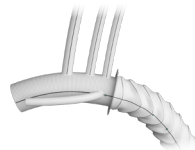
Island/En Bloc
Re-implantation of SAT*



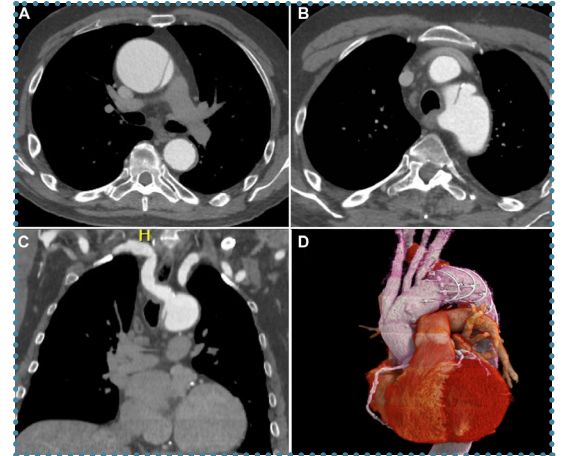

Zone 3
Standard technique



Zone 2
Distal LSA** anastomosis



Zone 0/1
Branch first technique



“The use of a specifically designed multibranched hybrid FET graft both simplifies the procedure and allows **more flexibility in dealing with challenging aortic arch anatomy**, such as in our patient with a KD and an ARSA”⁴

“The hybrid construction of the device provides **flexibility in planning further aortic reconstruction** using either endovascular or open techniques. Unlike other methods of hybrid and total endovascular arch repair, this technique appears to carry a **low stroke risk**.”⁵



WATCH ON VUMEDI
LSA Proximal Technique
with Thoraflex™ Hybrid

4. Besa et al. "Hybrid frozen elephant trunk for single-stage Kommerell Diverticulum and type A dissection." *Annals of Thoracic Surgery Short Reports*, 2023; 1, 285-288.
5. Landau et al. "Thoraflex Hybrid endovascular frozen elephant trunk device for treatment of complex aortic arch disease." *Journal of Vascular Surgery*, 2017; Abstract e68.
*SAT = Supra-Aortic Trunk
**LSA = Left Subclavian Artery



Discover solutions for every segment of the aorta
[terumoaoortic.com](https://www.terumoaoortic.com)

